



Letter to the Editor

Computed Tomography Scan for the Etiologies of Dysphagia



To the editor,

We previously publish a case series of nonaneurysmatic dysphagia aortica in the elderly in this journal.¹ Dysphagia aortica occurs because of extrinsic compression of the esophagus by the aorta. Diagnostic tools include chest radiography, esophagram, esophagogastroduodenoscopy (EGD) and computed tomography (CT). Here, we present an older patient suffering from lump sensation and his chest X ray revealed tortuous thoracic aortic and esophagram revealed persistent short segmental narrowing with smooth mucosal pattern at middle esophagus. The finally diagnosis is mediastinal mesothelioma by pleural biopsy under partial pleurectomy.

A 69-year-old man presented to our otorhinolaryngology department complaining of lump sensation over esophagus and dysphagia for 20 days. Chest radiography and esophagram were arranged at outpatient department. Chest X ray revealed tortuous thoracic aortic and esophagram revealed suspicious for persistent short segmental narrowing with smooth mucosal pattern at middle esophagus at T7 level. EGD was arranged due to abnormal esophagram and showed narrowing of the upper esophageal lumen (28 cm, from oral incisor) due to external compression and the mucosa was normal (Fig. 1A). Esophageal compression by an aneurysm is the most common cause of dysphagia aortica and it is usually observed in the elderly, especially in hypertensive patient with cardiomyopathy. According to

our previous experience, he was suspected to have dysphagia aortica. Then chest CT was arranged to rule out pulmonary lesion. However, the CT (Fig. 1B) scan found posterior mediastinal tumor with pleural seeding. We consulted chest surgeon for biopsy under partial pleurectomy and reveal malignant mesothelioma. The patient had received twelve times of chemotherapy. No recurrent tumor was noted under CT following up about one year till now.

Although there is no standard method to evaluate dysphagia caused by aorta compression, there are several tools to evaluate dysphagia aortica.² Chest radiography can show tortuous aorta or enlarged heart size. Endoscopic examination can show pulsatile extrinsic compression resulting in narrowing of the esophagus. Esophagram is a reliable method but result often show false negative due to liquid contrast medium.^{3,4} When dysphagia aortica is suspected on endoscopy, additional diagnostic procedures, especially CT is required. It is important to evaluate structure problem and anatomical relation between esophagus and peripheral organ, such as vessel, heart, lungs or mediastinum area. The clinical findings of dysphagia aortica may be similar to their etiologies. This symptom of dysphagia disease should be considered for the differential diagnosis in the elderly, including aging process of dysphagia aortica or neoplasms. I think computed tomography is the most crucial tool for diagnosis or dysphagia. Without the correct diagnosis by CT scan, the result and outcome may be a big disaster.

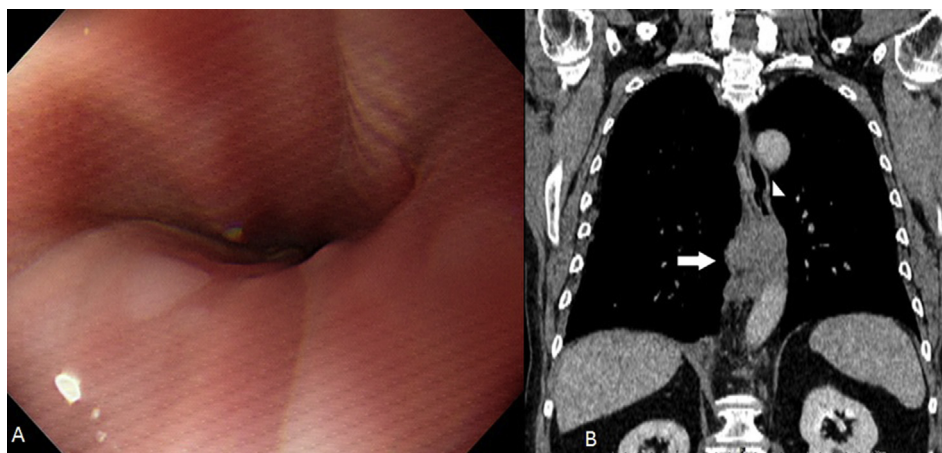


Fig. 1. A: EGD showed narrowing of the upper esophageal lumen due to external compression and the mucosa is normal. B: A 4.2×2.6 cm soft tissue mass (arrow) occupies esophageal (arrow head) wall eccentrically at middle third portion of esophagus and abutting thoracic descending aorta.

Conflict of interest

All authors declare to disclose any conflict of interest.

References

1. Chan YH, Hung CY, Shieh TY, et al. Nonaneurysmatic dysphagia aortica in the elderly: three case reports and literature review. *Int J Gerontol.* 2016;10: 52–55.
2. Cappell MS. Endoscopic, radiographic, and manometric findings associated with cardiovascular dysphagia. *Dig Dis Sci.* 1995;40:166–176.
3. Leonardi HK, Naggar CZ, Ellis Jr FH. Dysphagia due to aortic arch anomaly: diagnostic and therapeutic considerations. *Arch Surg.* 1980;115:1229–1232.
4. Mittal RK, Siskind BN, Hongo M, et al. Dysphagia aortica. Clinical, radiological, and manometric findings. *Dig Dis Sci.* 1986;31:379–384.

Yi-Hsueh Chan

*Division of Gastroenterology, Department of Internal Medicine,
MacKay Memorial Hospital, Taipei Campus, Taiwan*

*Graduate Institute of Clinical Medicine, National Taiwan University
College of Medicine, Taipei, Taiwan*

*Department of Nursing, MacKay Junior College of Medicine, Nursing
and Management, Taipei, Taiwan*

*Department of Medicine, MacKay Medical College, New Taipei,
Taiwan*

*Chien-Yuan Hung, Tze-Yu Shieh, Ming-Jen Chen**
*Division of Gastroenterology, Department of Internal Medicine,
MacKay Memorial Hospital, Taipei Campus, Taiwan*

*Department of Nursing, MacKay Junior College of Medicine, Nursing
and Management, Taipei, Taiwan*

*Department of Medicine, MacKay Medical College, New Taipei,
Taiwan*

* Corresponding author. Division of Gastroenterology, Department
of Internal Medicine, MacKay Memorial Hospital, No. 92, Sec. 2,
Chungshan North Road, Taipei, Taiwan.
E-mail address: mingjen.ch@msa.hinet.net (M.-J. Chen).

10 January 2018

Available online 26 March 2018